

Case Report
-------------

## Computed tomographic diagnosis of iliac vein compression (May-Thurner) syndrome in a patient with gastric cancer: Initial experience

Osamu Takata, Masako Sakuragi, Hirokazu Kiyozaki,  
Takayoshi Yoshida, Fumio Konishi

### Abstract

We report a case of an initial experience of "Iliac compression syndrome". A 73-year old male underwent a distal gastrectomy with an en-bloc lymphadenectomy (D2). He presented with persistent painful severe swelling of his left lower extremity on postoperative day 13. According to these typical features of the swollen lower extremity, we diagnosed as deep venous thrombosis (DVT). Ultrasonography and abdominopelvic computed tomography (CT) revealed a massive amount of thrombus in the iliofemoral vein and his clot proceeded close to the periphery of the bifurcation of common iliac vein, despite the appropriate use of systemic heparin to prevent the occurrence of embolism. Thereafter, we retrospectively reviewed the preoperative CT findings demonstrated the compression of the left common iliac vein by the right common iliac artery and lumbar vertebra. He was diagnosed to have "Iliac compression syndrome" according to his clinical findings and those of an imaging examination. DVT is the most important complications which may lead to sudden death after an operation. In this case, DVT was experienced after a gastrectomy, while being administered systemic heparin. We herein report this rare venous anomaly which is called either "May-Thurner syndrome" or "Iliac compression syndrome".

(**Key words:** Deep venous thrombosis (DVT), Iliac compression syndrome, May-Thurner, Gastric cancer)

### Introduction

Deep venous thrombosis (DVT) is one of the fatal complications which may lead to the onset of acute pulmonary embolism. This infarction may also sometimes be related to sudden death after an operation. As a result, DVT should be strictly avoided by both patients and surgeons. In general, systemic heparinization may be effective for decreasing the incidence of DVT. Therefore low dose of heparin is approved for use in perioperative anticoagulants at present all over the world. In this case, DVT was experienced after a gastrectomy, despite the appropriate use of heparin. We retrospectively reviewed the CT findings, and a congenital narrowing of the left common iliac vein due to pressure from the overlying right iliac artery was recognized. We herein report this rare venous anomaly which is called either "May-Thurner

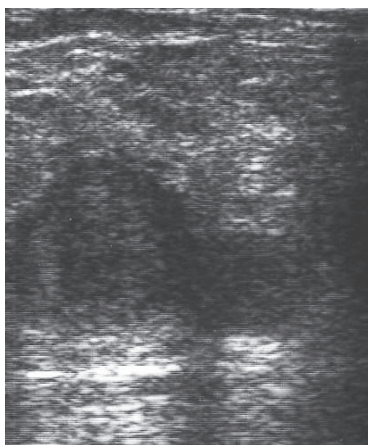


Figure 1 Ultrasonography showed numerous clots forming in the right popliteal vein to the ipsilateral femoral vein. The clots could be clearly recognized.

syndrome<sup>1)</sup>” or “Iliac compression syndrome<sup>2)</sup>” while also making a review of pertinent the literature.

### Case

A 73-year old male underwent a distal gastrectomy with an en-bloc lymphadenectomy (D2) while being administered systemic heparin to prevent the occurrence of embolism. He recovered well until postoperative day 12. However he presented with persistent painful severe swelling of his left lower extremity on postoperative day 13. His thigh became swollen and thereafter rapidly became very thick. These typical features of the swollen lower extremity were easily identified as DVT. As far as he knew, he had rarely felt any pain or discomfort in his thighs. Ultrasonography (US) revealed a lot of clotting in the left iliofemoral vein (Figure 1). Abdominopelvic CT also demonstrated a massive amount of thrombus in the iliofemoral vein and his clot proceeded close to the periphery of the bifurcation of common iliac vein (Fig-

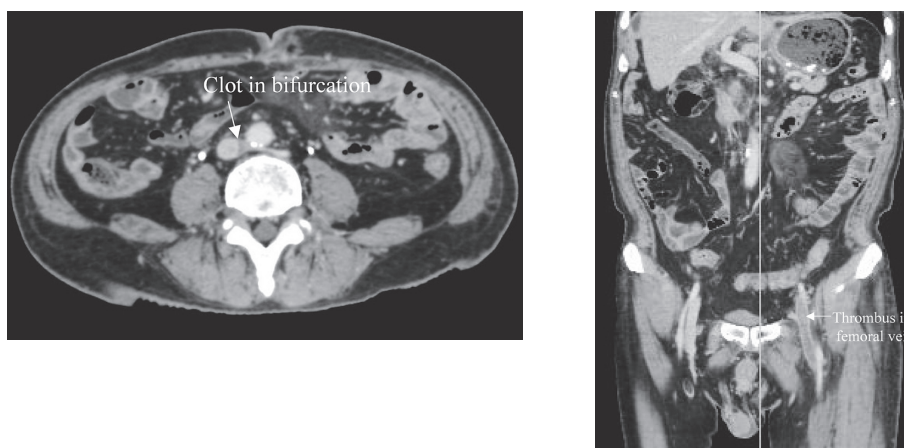


Figure 2 An abdominopelvic CT image revealed a massive amount of thrombus in the left iliofemoral vein, and this thrombus closed to the periphery of the vascular bifurcation.

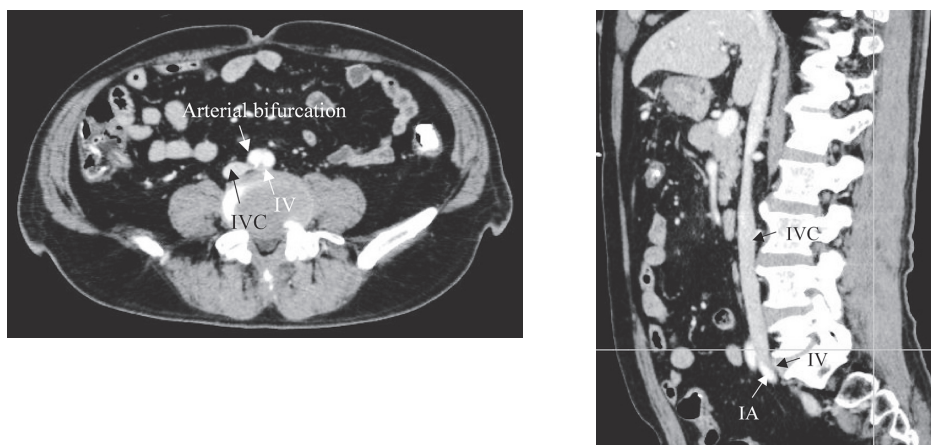


Figure 3 A coronal and sagittal CT of the level of the pelvic inlet demonstrated the compression of the left iliac vein (IV) by the right iliac artery (IA) and lumbar vertebra. At this time, the clot was not recognized to be in the iliofemoral vein.

ure 2). In addition, a preoperative CT examination demonstrated the compression of the left common iliac vein by the right common iliac artery and lumbar vertebra (Figure 3). He was diagnosed to have "Iliac compression syndrome" or "May-Thurner syndrome" according to his clinical findings and those of an imaging examination. As a result, he was treated with systemic heparinization around the clock. The total amount of heparin was 75000 units parenterally (15000 unit/day for five days in a row). In addition, a temporal inferior vena cava (IVC) filter was used to prevent pulmonary embolism via the right internal jugular vein. He felt better immediately after the timely treatment, however, his left edematous lower extremity remained the same, and he also failed to achieve thrombolysis in his iliofemoral vein (Figure 4). As a result, tissue plasminogen activator (tPA) (400000 unit/once) was systemically initiated with heparin. However, he did not receive any endovascular treatment such as a thrombectomy or stent placement,

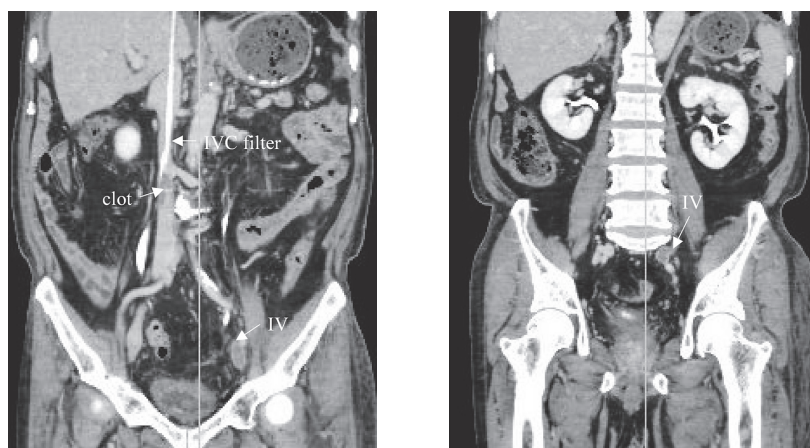


Figure 4 The clot still remained in the left iliac vein (IV) even after administering the treatment for thrombolysis and thereafter a new thrombus developed at the lower end of inferior vena cava (IVC) filter.

because of his poor prognosis. Based on clinical judgment, no IVC filter was placed. And then, the patient was discharged from the hospital with a persistent clot, and prescribed the following treatment regimen: 3.5mg of Warfarin daily. The control level of PT-INR was 2.0-2.5.

## Discussion

DVT is a well known complication, because DVT can sometimes lead to severe complications such as pulmonary infarction. Particularly, prolonged bed rest or a problem with postoperative status may be the cause of such an embolism. Systemic heparin is frequently administered after the operation in order to prevent embolism in many hospitals. In this case, we experienced a patient with postoperative DVT, in spite of the fact that heparin was appropriately administered. He originally had a thrombotic predisposition which was related to a narrowing of the left common iliac vein. This phenomenon is called "iliac vein compression syndrome, May-Thurner syndrome, ilio caval compression syndrome or Cockett syndrome" based on the use of various terminology. This left congenital narrowed common iliac vein is caused by the compression of the overlying right common iliac artery<sup>1)-3)</sup>. Therefore, iliac compression syndrome is not only an illness but also a congenital vascular anomaly. This anomaly may not cause this symptom at mild and moderate degrees of coarctation. However, severe degrees of coarctation can lead to the obstruction of the blood flow, thus resulting in a swollen and painful thigh. This anatomical variant of the left extremity is not so infrequent<sup>4)</sup>. The incidence of DVT with malignant disease is approximately two percent of all cases, but the exact ratio of DVT, which causes to the compression of the left common iliac vein is unknown<sup>2)5)</sup>. However, this syndrome clearly is associated with the possibility of venous thrombosis, thus resulting in swelling and pain of the left lower extremity<sup>6)</sup>. In past years, we experienced cases of pulmonary embolism after surgery. Thereafter, a low dose of heparin has instead been used during the perioperative period (2500 unit/day, until postoperative ambulation). We experienced no patients with either lung infarction or DVT until encountering this case. This was the first experience that a patient developed DVT after a gastrectomy, despite the use of systemic heparin for the thrombosis. We therefore retrospectively reviewed the preoperative CT finding, and thus identified a congenitally narrowed left common iliac vein due to an obvious compression of the overlying right iliac artery (Figure 3). This patient thus demonstrated risk factors for potentially developing DVT. In general, this anomaly has previously been identified as May-Thurner syndrome<sup>1)</sup>. Ehrlich and Krumbhaar reported that ninety-eight of 412 cadavers demonstrated an obstruction of the left iliac vein in 1943<sup>7)</sup>. In addition, R May and J Thurner firstly explained the cause of DVT based on the findings of 430 cadavers in 1957<sup>1)</sup>. Basically, the blood flow from the lower extremity and the pelvis goes through the deep veins into the common iliac vein and then to inferior vena cava and the heart. In addition, the right common iliac artery lies on top of the left common iliac vein. This close relationship causes a modification of the vein due to the transmitted arterial beating, thus leading to a narrowing of the left iliac vein<sup>1)-3)</sup>. Such compression thus permanently influences the deformation over the long term. As a result, this vascular anomaly has been reported to be acquired and not be precisely congenital, furthermore this syndrome may also progressively worsen as the patient ages<sup>5)</sup>. Imaging examinations such as CT, Venography and Intravascular ultrasound (IVUS) scanning can thus play a significant role in the diagnosis. In particular, IVUS have a better diagnostic sensitivity (>90%) than that of venography (66%), and is also significant useful examination for indication for stent placement<sup>12)</sup>. And next, three dimensional CT examination can clearly reveal the ana-

tomical relationship between the right iliac artery and the left iliac vein and thereby helping to accurately predict the risk of either DVT or more serious complications. In addition, CT is also less invasive than a venography and IVUS. Unfortunately, we only evaluated the staging of cancer status, (i.e. lymph node swelling, peritoneum dissemination or distant metastasis). As a result, we were unaware of the presence of this rare anomaly. This variant may be frequently overlooked, if surgeons are not aware of this disease. A couple of surgical procedures have been candidates for treatment in the past, (i.e. venous graft bypass, cutting of the right iliac artery and replacement behind the left iliac vein or inferior vena cava, lifting iliac artery off the vein by a tissue sling or flap.) Currently, some endovascular treatments such as a thrombectomy or stent placement have been reported. Usually, balloon dilatation and stent placement<sup>(8)9)</sup> have been put into the coarctation via the femoral vein after the thrombolytic treatment via the ipsilateral popliteal vein<sup>(10)11)12)</sup>. Thereafter, long-term Warfarin treatment is mandatory. In this case, no aggressive procedures were required due to the results of the histopathological prognosis. The patient is presently being followed closely with Warfarin daily for life due to the risk of developing complications associated with pulmonary infarction.

In conclusion, iliac compression syndrome or May-Thurner syndrome, which are related with DVT, is a rare vein anomaly which could lead to fatal complications, such as pulmonary embolism. It is possible to detect this syndrome based on the findings of CT. Therefore, if persistent thigh edema and pain is recognized during the perioperative period, this syndrome should therefore be included in the differential diagnosis and aggressive endovascular treatments, such as selective thrombolytic treatment and stent placement of the left common iliac vein, should also be considered when appropriate.

## References

- 1) May R, Thurner J. The cause of the predominantly sinistral occurrence of thrombosis of the pelvic veins. *Angiology* 1957; 8: 419-427.
- 2) Taheri SA, Williams J, Powell S, et al. Iliocaval compression syndrome. *Am J Surg* 1987; 154: 169-172.
- 3) Cockett FB, Thomas ML. The iliac compression syndrome. *Br J Surg* 1965; 52: 816-821.
- 4) Heniford BT, Senler SO, Olsofka JM, Carrillo EH, Bergamini TM. May-Thurner syndrome: management by endovascular surgical techniques. *Ann Vasc Surg* 1998; 12: 482-486.
- 5) Barbaros E. Cil, Erhan Akpınar, Musturay Karcaaltincaba, Devrim Akinci. Case 76: May-Thurner Syndrome. *Radiology* 2004; 233: 361-365.
- 6) Sakakibara Y, Kajiraoka Y: Iliac Compression Syndrome. *Circulation* 1998; 4: 376.
- 7) Ehrich WE, Krumbhaar EB. A frequent obstructive anomaly of the mouth of the left common iliac vein. *Am Heart J* 1943; 26: 737-750.
- 8) Berger A, Jaffe JW. Iliac compression syndrome treated with stent placement. *J Vasc Surg* 1995; 21: 510-514.
- 9) Buelens C, Vandenbosch G, Stockx L, et al. Cockett syndrome: initial results with percutaneous treatment in 6 patients. *J Belge Radiol* 1996; 79: 132-135.
- 10) Patel NH, Stookey KR, Ketcham DB, Cragg AH. Endovascular management of acute extensive ilio-femoral deep venous thrombosis caused by May-Thurner syndrome. *J Vasc Interv Radiol* 2000; 11: 1297-1302.

- 11) O'Sullivan GJ, Semba CP, Bittner CA, et al: Endovascular management of iliac vein compression (May-Thurner) syndrome. *J Vasc Interv Radiol* 2000; 11: 823-836.
- 12) Seshadri Raju, Peter Neglen. High prevalence of nonthrombotic iliac vein lesions in chronic venous disease: A permissive role in pathogenicity. *J. Vas. Surg* 2006; 44: 136-144.

# CT 検査にて診断しえた胃癌術後の Iliac compression syndrome (May-Thurner syndrome) の一例

高田 理 清崎 浩一 櫻木 雅子  
吉田 卓義 小西 文雄

## 要 約

我々は、胃癌術後に発生した右総腸骨動脈圧迫による左総腸骨静脈の器質的狭窄 (May-Thurner syndrome) を起因とした希な深部静脈血栓症の一例を経験したので報告する。症例は73歳、男性。胃癌に対して、2群リンパ節郭清を伴う幽門側胃切除術を施行した。術中および術後に、肺血栓症および深部静脈血栓症予防のためにヘパリンナトリウムの皮下注射を行った。術後13日目に、左下肢の痛みと腫脹が出現した。下肢血管超音波検査および腹部骨盤CT検査を施行したところ、左腸骨大腿静脈から総腸骨静脈分岐部末梢まで血栓を認め、深部静脈

血栓症と診断した。術前の腹部骨盤CTを再確認したところ、右総腸骨動脈と椎骨の圧迫による左総腸骨静脈の器質的狭窄 (May-Thurner syndrome) と断定した。本疾患の発生頻度は約0.2%であり、本疾患を起因とした深部静脈血栓症は希であると考えられている。深部静脈血栓症は、発症すると死亡にいたることもある重大な合併症の一つであるため、術前に静脈血栓を起こしうる異型を認識する必要がある。本疾患は、CT検査にて同定することが可能な異型であり、外科医が手術を行う際に認識すべき異型の一つであると思われた。