

Case Report

Real-time three-dimensional echocardiographic assessment of neonatal cardiac tumors

Daisuke Matsubara^{1,3)}, Shigeki Matsubara²⁾, Yutaka Kikuchi^{1,3)}, Tomoyuki Kuwata²⁾, Hirohiko Shiraishi¹⁾, Masaru Hoshina^{1,3)}, Mariko Y Momoi¹⁾

Abstract

Two-dimensional echocardiography revealed cardiac tumors in the fetus of a mother with tuberous sclerosis. After birth, six cardiac tumors were demonstrated by two-dimensional echocardiography. Real-time three-dimensional echocardiography was performed, which demonstrated good cardiac wall motility. Data set analysis revealed a 7th tumor adjacent to the aortic valve: normal aortic valve movements and the absence of aortic outflow obstructions were demonstrated. These findings convinced us to adopt a watch-and-wait strategy. The cardiac tumors had regressed in size at 1 year of age. Real-time three-dimensional echocardiography may be useful in the assessment of neonatal cardiac tumors.

(Keywords: cardiac tumor; neonate; real-time three-dimensional echocardiography)

Introduction

Widespread employment of fetal echocardiography in pregnancy check-ups has increased the chance of detecting fetal cardiac tumors, and thus also the chance of treating them during the neonatal period.

Rhabdomyoma is the most common infantile cardiac tumor, with 51-86% having tuberous sclerosis (TS), an autosomal dominant trait¹⁾. While infantile cardiac tumors with TS frequently regress after birth, some lead to cardiac failure or neonatal death, which is associated with the tumor features, including the size and location of the tumors, or with their influence on heart movements^{2,3)}. In particular, outflow obstructions or valve movement disturbances caused by the tumors may sometimes become life-threatening^{2,3)}. Therefore, prompt evaluation of the tumors after birth is required.

Real-time three-dimensional echocardiography (RT3DE) enables physicians to grasp how the heart structure and cardiac tumors actually appear in three dimensions. Once a RT3DE dataset is acquired, images in any desired plane can be obtained, enabling later analysis. We employed RT3DE to access cardiac tumors during the neonatal period and suggest its possible merits in this situation.

Case Report

Conventional two-dimensional (2D) ultrasound revealed multiple intra-ventricular masses (inset of Figure 1) at the 32th week of gestation in a fetus of a primiparous woman with TS, leading to a probable diagnosis of cardiac rhabdomyoma associated with fetal TS. Fetal hydrops and dysarrhythmia, negative

prognostic indicators²⁾, were not observed. At the 39th week, due to failure of labor to progress, the woman gave birth abdominally to a female infant weighing 2202 g with a 5-minute Apgar score of 9.

The findings of auscultation, electrocardiogram and chest-X-ray were normal. Trans-thoracic 2D echocardiography immediately after birth revealed cardiac tumors. Two left ventricular (LV) tumors, the largest tumor (14.4×5.0 mm) in the inter-ventricular septum and another tumor (5.6×5.0 mm) in the LV free wall, could be observed (Figure 1). Four right ventricular (RV) tumors of 5.0×4.0 , 6.0×4.7 , 3.6×3.6 , 2.3×2.0 mm, respectively, were also observed, with all located at a distance from the RV outflow. Otherwise, the cardiac structure was normal, with left ventricular ejection fraction of 75%.

Trans-thoracic RT3DE (iE33; Philips Electronics Healthcare, Bothell, WA, USA) with a 2-7MHz matrix array transducer (X7-2) was performed. Figure 2 (a-d) indicates 3D-rendered images (a-c) and 3D images (d). Two LV tumors were seen, one from the septum and the other from the LV free wall (Figure 2d), which did not prevent outflow. The dataset for RT3DE was acquired. Analysis of the dataset revealed another small LV tumor just adjacent to the aortic valve. Figure 2a, b and c, especially Figure 2c, indicate that this tumor appeared to be attached to the aortic valve; however, it did not protrude out of the LV into the aorta. Good aortic valve movements and absence of outflow obstructions were shown. Well-organized movements of both the ventricular free wall and inter-ventricular septum were also observed. The absence of left ventricular outflow obstruction was indicated also by pulsed Doppler echocardiography. We therefore employed a watch-and-wait strategy.

Cerebral magnetic resonance imaging 39 days after birth revealed cortical tubers, bilateral tricorn subependymal nodules, compatible with TS. The patient was free from cardiac symptoms and the cardiac tumors had regressed in size at 1 year of age. The parents gave oral consent to reporting and the patient's anonymity was preserved.

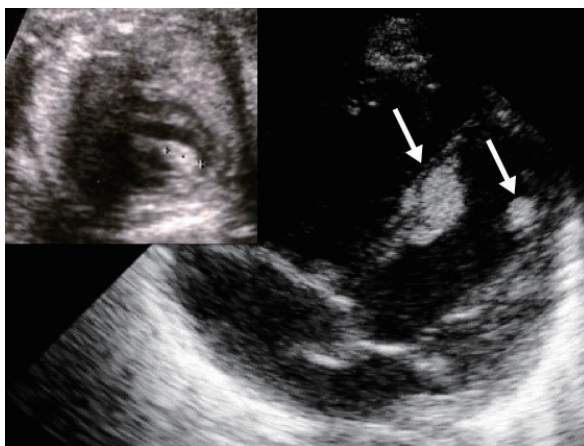


Figure 1 Two-dimensional echocardiographic findings of left ventricular tumors during fetal (inset) and neonatal periods.

Left arrow indicates the largest left ventricular (LV) tumor located in the inter-ventricular septum and right arrow indicates the tumor in the LV free wall.

Inset: mark (+) indicates the LV tumor during the fetal period, corresponding to the left-arrow tumor.

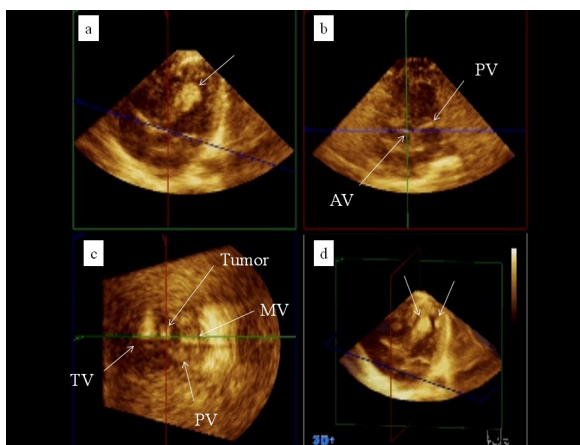


Figure 2 Real-time three-dimensional echocardiographic findings of cardiac tumors during neonatal period.

Figure 2 a, b, and c indicate 3D-rendered images in the plane of the aortic valve. Line (green, red, or blue) indicates the plane of the aortic valve. Each plane indicated by green, red, and blue lines in (d) is shown in (a), (b), and (c), respectively. The largest LV tumor can be observed in (a) (arrow) and (d) (left arrow). Right arrow in (d) indicates LV free wall tumor. Figure 2c (arrow marked Tumor) indicates another LV tumor.

AV, aortic valve; PV, pulmonary valve; MV, mitral valve; TV, tricuspid valve

Discussion

We report the observation of cardiac tumors by RT3DE during the neonatal period. While cardiac tumors associated with TS frequently regress and require no treatment, some tumors lead to cardiac failure³⁾. Webb et al.³⁾ reported that of 15 children with symptoms of cardiac rhabdomyoma, 5 died of heart failure. Factors of poor prognosis were tumor size, low cardiac wall motility, and the tumor's spatial relationship with the heart structure^{2,3)}. Outflow obstructions or valve movement disturbances were also factors of poor prognoses^{2,3)}, and frequently required surgery⁴⁾.

Employment of RT3DE for assessing cardiac tumors in adult patients has already been described^{5,6)}. Plana⁵⁾ claimed that RT3DE may be useful to diagnose the size and location, especially its relationship to other structures in adult cardiac tumors. Reddy et al.⁶⁾ also described an adult patient; 2D identified only one or possibly two cardiac masses, while RT3DE showed three masses and also delineated the precise location of their attachment. These merits of RT3DE for evaluating cardiac tumors may be larger in infantile patients, in which a small heart is occupied by multiple tumors.

In the present case, RT3DE enabled the identification of an additional tumor adjacent to the aortic valve. Rapid movement of the aortic valve may have prevented us from finding this 7th tumor by 2D. While performing RT3DE, we noticed "something" adjacent to the aortic valve but could not identify it confidently. Later analysis of the RT3DE dataset revealed the presence of this 7th tumor. We therefore closely observed whether LV outflow obstructions or aortic valve movement disturbances were present. They were absent, which led us to adopt a wait-and-watch strategy. If we had not noticed this 7th tumor, we would have employed a similar wait-and-watch strategy. In this case, the detection of the 7th tumor

did not actually influence the treatment strategy; however, this can be said only in retrospect. If RT3DE analysis had shown ominous findings associated with this 7th tumor, another strategy may have been employed.

Putting the issue of this additional tumor aside, the relationship with the surrounding structure of the cardiac tumors was well identified by RT3DE. Good motility of the valve, free ventricular wall and inter-ventricular septum was directly demonstrated by RT3DE. Furthermore, as suggested by another report⁵⁾ and also by the present case, the RT3DE dataset can be acquired by a small number of RT3DE captures. This may give us much information and reduce the time; rapid examination is preferable for neonates who cannot lie still for a long time.

In conclusion, RT3DE showed how the heart structure and the cardiac tumors actually appeared in three dimensions and thus helped us to grasp the anatomical relationship in a direct manner. RT3DE dataset enabled the view of the desired plane and also enabled later detailed analysis. All these merits of RT3DE have been illustrated in this case; however, RT3DE has lower resolution than 2D. Combined use of 2D and RT3DE may be practical in the assessment of neonatal cardiac tumors. Further study is needed regarding how RT3DE should be employed in the assessment of neonatal cardiac tumors.

References

- 1) Harding CO, Pagon RA: Incidence of tuberous sclerosis in patients with cardiac rhabdomyoma. *Am J Med Genet* 37:443-446, 1990.
- 2) Chao AS, Chao A, Wang TH, et al.: Outcome of antenatally diagnosed cardiac rhabdomyoma: case series and a meta-analysis. *Ultrasound Obstet Gynecol* 31:289-295, 2008.
- 3) Webb DW, Thomas RD, Osborne JP: Cardiac rhabdomyomas and their association with tuberous sclerosis. *Arch Dis Child* 68:367-370, 1993.
- 4) Jacobs JP, Konstantakos AK, Hokkand FW 2nd, et al.: Surgical treatment for cardiac rhabdomyomas in children. *Ann Thorac Surg* 58:1552-1555, 1994.
- 5) Plana JC.: Added value of real-time three-dimensional echocardiography in assessing cardiac masses. *Curr Cardiol Rep* 11:205-209, 2009.
- 6) Reddy VK, Faulkner M, Bandarupalli N, et al.: Incremental value of live/real time three-dimensional transthoracic echocardiography in the assessment of right ventricular masses. *Echocardiography* 26:598-609, 2009.

3Dエコー法による新生児心臓腫瘍の観察

松原 大輔^{1,3)}, 松原 茂樹²⁾, 菊池 豊^{1,3)}, 桑田 知之²⁾,
白石裕比湖¹⁾, 保科 優^{1,3)}, 桃井真里子¹⁾

要 約

結節性硬化症母胎児に心臓腫瘍が認められた。新生児期に2Dエコー法が行われ、心臓内に6個の腫瘍が認められた。3Dエコー法では、これら腫瘍が立体視できた。また、2Dエコー法では確認できなかった7個目の腫瘍が大動脈弁近傍に認められた。これら腫瘍は流出路閉塞を示さず、また心臓壁や心室中隔の良好な

運動が3Dエコー法で確認できた。新生児は心機能異常を示さず、経過観察された。Magnetic resonance imagingで脳内石灰化病変が認められ、結節性硬化症に伴う心臓良性腫瘍だと臨床診断した。3Dエコー法は新生児の心臓腫瘍を評価するツールとして有用である可能性が高い。

1) 自治医科大学医学部小児科
2) 自治医科大学医学部産婦人科
3) 真岡赤十字病院小児科