

Case Report

Placental abruption after minor maternal trauma: The need for immediate cardiotocographic monitoring

Kouhei Odagiri¹⁾, Shigeki Matsubara^{1,2)}, Yosuke Baba¹⁾, Tomoyuki Kuwata¹⁾,
Kazuhiko Shimada¹⁾, Takashi Watanabe¹⁾, Akio Izumi¹⁾, Mitsuaki Suzuki¹⁾

We report a 31-week-gestational woman who suffered placental abruption after a very minor maternal trauma. Although she did not show genital bleeding or abdominal pain, symptoms characteristic of placental abruption, an immediate cardiotocogram and echogram revealed the placental abruption. An emergency cesarean section was performed and she gave birth to a healthy preterm infant. In the care of traumatized pregnant women, an immediate cardiotocographic examination should be done at the same time as the systemic physical examination are performed, even though the trauma may appear quite minor and even if she makes no obstetrical complaints.

(key words : trauma, traffic accident, placental abruption, cardiotocogram)

I. Introduction

Trauma to the mother during pregnancy can lead to various pregnancy disorders, including spontaneous abortion, placental abruption, preterm delivery, fetomaternal transfusion, and fetal death.^{1,2} Among them, most attention focused on the association of maternal trauma and the occurrence of placental abruption. A recent Canadian report showed that among 68 pregnant trauma patients, eight suffered placental abruption and they all had associated fetal death, indicating that placental abruption was the strongest predictor of fetal mortality in traumatized mothers.¹ It is well known that the severer the degree of the trauma, the more frequently placental abruption occurs.^{2,3} Indeed, abruption complicates up to 50% of "major" trauma.² It has been reported that "minor" injury, although less frequent, can also lead to this disorder, but in these cases, the maternal obstetrical signs (genital bleeding, abdominal pain or tenderness, etc) usually concur.⁴ Therefore, physicians caring for pregnant women may overlook this disorder if the trauma is very minor, and if maternal symptoms are absent. In this report, describing a case, we would like to sound an alarm, showing that placental abruption may occur even after very minor trauma and even without maternal symptoms and complaints.

II. Case Report

A 28-year-old primigravid woman was taken to the Emergency Unit of Jichi Medical School

1) Department of Obstetrics and Gynecology, Jichi Medical School, Tochigi, Japan
Correspondence :

2) Shigeki Matsubara
Department of Obstetrics and Gynecology, Jichi Medical School, 3311-1, Minamikawachi-machi, Kawachi-gun, 329-0498 Tochigi, Japan

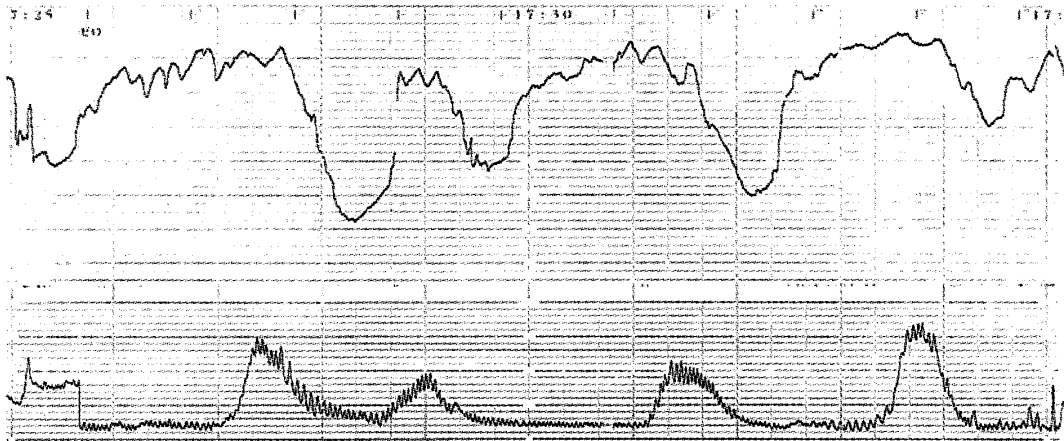


Fig. 1 Cardiotocogram.
This cardiotocogram was obtained just after admission. A non-reassuring fetal heart rate pattern is recognizable.

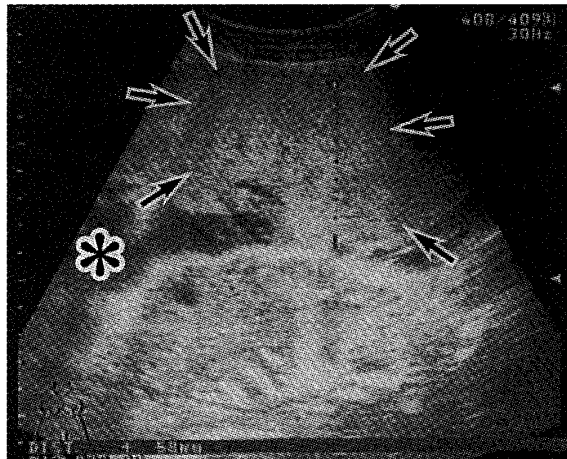


Fig. 2 Echogram.
This echogram indicates the abnormally large thickness of the placenta (arrows ; 58 mm : normal range ; within 30 mm), a sign of placental abruption. An asterisk indicates amniotic fluid space.

at 31 weeks of gestation immediately after being hit by a car. Just after receiving a routine periodical obstetrical examination at Jichi Medical School, she was on her way home in her husband's car, sitting in the passenger seat wearing an ordinary triangular seat belt. A car then hit her car broadside. The speed of both cars was considered to be approximately 20 km/hr or less, and the air bag did not inflate. She complained of slight pain in her right elbow and knee, but denied abdominal pain, genital bleeding, and uterine contraction. There were no abrasions/contusions recognizable on her abdomen, including a seat belt mark. Her vital signs were unremarkable. Immediately after her arrival (only five min) cardiotocography was performed, which indicated a non-reassuring fetal heart rate pattern (Fig. 1). An echogram showed an anteriorly-lying placenta of 5.8 cm thickness (Fig. 2), an abnormal thickness. These findings indicated that she had suffered from placental abruption with fetal distress, and thus an emergency cesarean section was performed. She gave birth to a female infant weighing 1950g

with an APGAR score of 6 at 1 min and 8 at 3 min, respectively. A retroplacental hematoma occupying approximately one-third of the placental maternal surface was observed, confirming the diagnosis of placental abruption. The laboratory data at admission, reported after the caesarean section was performed, were unremarkable except for a slight elevation of the serum fibrin degradation product (FDP : $9.9 \mu\text{g/ml}$; normal range <5). The mother and the baby were discharged at eight and 51 days, respectively, with no complications. The baby is now doing well with no neurological or other sequelae.

III. Discussion

This case indicated that¹⁾ even very minor maternal trauma can induce placental abruption, a catastrophic condition for both the mother and the fetus,²⁾ this disorder is not always accompanied by maternal obstetrical signs such as bleeding and abdominal pain, and³⁾ immediate fetal cardiotocography is strongly recommended.

Even "minor" injury can induce placental abruption. Three previous reports in a large population showed that in "minor", non-catastrophic trauma during pregnancy, this disorder occurred in 2.4% (5/205),⁴ 2.6% (6/233),⁵ and 4% (3/75),⁶ respectively. Dahmus and Sibai⁵, combining their own and other data, summarized that among 814 mothers who were involved in non-catastrophic trauma, 17 women (17/814=2.1%) suffered placental abruption. Goodwin and Breen⁴, analyzing 205 cases with minor trauma, reported that obstetrical findings/symptoms (bleeding, abdominal tenderness, etc.) were highly associated with complications including placental abruption, and concluded that the pregnancy was rarely affected in patients who lacked these findings/symptoms. Our case did not concur with their view. Although there were uterine contractions on the cardiotocogram, this woman denied uterine contractions at admission. She showed no genital bleeding and did not complain of abdominal pain. She came to the hospital only to relieve her anxiety and to prepare for the judicial issue, and not for the relief of any subjective complaints. Indeed, she had no medical/obstetrical complaints except for slight pain in her knee and elbow. Neither was any evidence of abdominal injury obtained. Therefore, physicians caring for pregnant women must bear in mind the possible occurrence of placental abruption no matter how minor the trauma may appear and even if the woman makes no obstetrical complaints : the absence of external maternal injury should not decrease the physician's level of concern.

Direct hit (assault), falls, and traffic accidents are three major causes of non-catastrophic maternal trauma.^{4,5} Traffic accidents accounted for 22% (56/205)⁴ and 28% (66/233)⁵ of these minor injuries. Among minor injuries caused by traffic accidents, placental abruption occurred 1/56 (1.8%)⁴ and 2/66 (3.0%).⁵ Therefore, out of 1000 pregnant women with minor injuries, there are approximately 250 women injured by traffic accidents, among which approximately five women may suffer from placental abruption. Due to this limited population of cases with placental abruption caused by minor traffic injuries, clinical features of this condition have not yet been fully determined. Reis et al.³, however, describing 12 pregnant women who suffered from placental abruption after traffic accidents (minor+major), reported that higher speeds (over 48 km/hr) and higher injury severity scores predicted the occurrence of placental

abruption. Once again, our case, being at a slow speed and suffering from very minor injury, did not concur with this observation by Reis et al.³

This case offers other important practical advice : fetal cardiotocography should be performed as soon as possible. This is in good agreement with some other researchers.^{5,6} In this case, the effect on the mother and the fetus may have been catastrophic, if the slight injuries to her extremities were first taken care without immediately receiving fetal monitoring. In the case of traffic accidents in Japan, as in other countries, detailed physical examinations and their description are routinely performed for judicial reasons. Although the detailed mechanism of traumatic placental abruption remains unclear, it is believed to occur at the time of trauma.^{6,7} Placental separation is likely caused by deformation of the elastic myometrium around the relatively inelastic placenta.² Therefore, fetal monitoring should be done immediately upon confirmation that there are no serious or life-threatening condition of the mother. Care providers for pregnant women, no matter their major (obstetrics, family medicine, emergency care medicine, etc), must not overlook placental abruption, which can be detected by a simple procedure ; a cardiotocography. Surveillance for the fetus must precede judicial preparation.

IV. References

- 1) Yeo AJ, Gana TJ and McLellan BA. Predictors of fetal mortality in pregnant trauma patients. *J Trauma* 42 : 782-785, 1997
- 2) Cunningham FG, Gant NF, Leveno KJ, et al. Critical care and trauma. In : Williams Obstetrics, 21th edn. eds Cunningham FG, Gant NF, Leveno KJ, et al. New York : McGraw-Hill, 2001 ; 1159-1180.
- 3) Reis PM, Sander CM and Pearlman MD. Abruptio placentae after auto accidents. A case control study. *J Reprod Med* 45 : 6-10, 2000
- 4) Goodwin TM and Breen MT. Pregnancy outcome and fetomaternal hemorrhage after noncatastrophic trauma. *Am J Obstet Gynecol* 162 : 665-671, 1990
- 5) Dahmus MA and Sibai BM. Blunt abdominal trauma : Are there any predictive factors for abruptio placentae or maternal-fetal distress? *Am J Obstet Gynecol* 169 : 1054-1059, 1993
- 6) Pearlman MD, Tintinalli JE and Lorenz RP. A prospective controlled study of outcome after trauma during pregnancy. *Am J Obstet Gynecol* 162 : 1502-1510, 1990
- 7) Kettel LM, Branch DW and Scott JR. Occult placental abruption after maternal trauma. *Obstet Gynecol* 71 : 449-453, 1988

軽症外傷後の胎盤早期剥離： 迅速な胎児心拍モニター実施の必要性

小田切幸平
桑田 知之

松原 茂樹
島田 和彦
泉 章夫

馬場 洋介
渡辺 尚
鈴木 光明

要 約

外傷性胎盤早期剥離は妊婦の腹部重症外傷に高率に合併する。時に軽症外傷にも合併するが、この際にも性器出血や腹痛などの症状を伴うことが多い、と報告されてきた。今回、軽微交通外傷後に発症した無症候性胎盤早期剥離症例を経験した。症例は28才、初妊、初産婦。妊娠31週。車同士の側面衝突。車は小破程度でエアバッグ作動せず。妊婦は助手席で3点式シートベルトを装着しており、腹部打撲の自覚なし。事故後直ちに当病院救急外来へ救急車搬送された。妊婦は右肘、右膝の軽度疼痛を訴え、同部に軽度腫脹を認めたが、他の外傷や腹部ベルト圧痕を認めず、性器出血や腹痛の訴えもなかった。全身の check up に並行して胎児心拍モニタリングを行ったところ、non-reassuring fetal

heart rate pattern を認め、腹部超音波検査では胎盤の異常肥厚像を認めた。胎盤早期剥離による胎児ジストレスと判断、緊急帝王切開が行われた。新生児は1950gの女児でアプガー値は、6点、8点(1, 3分)。胎盤母体面の1/3を占める胎盤後血腫を認め、胎盤早期剥離が確定された。母体DICや母児間輸血のサインは認めず、母児共健康退院となった。胎盤早期剥離は軽症外傷にも合併し得る。性器出血、腹痛などの症状がなくても、また腹部打撲の自覚がなくても本症は起こり得る。軽症外傷、ことに軽症交通外傷では、受傷妊婦に生命の危険のないことを確認後、胎児心拍モニタリングを傷処置や傷状態の記録(訴訟に対する証拠保全)に先行させて施行すべきである。