

Case Report

Aortic root false aneurysm from gelatin-resorcinol-formaldehyde (GRF) glue following surgical treatment for type A dissection

Yasuhito Sakano^{*}, Tsutomu Saito^{*}, Yoshio Misawa^{*}

Abstract

It has recently been reported that tissue toxicity from formaldehyde can cause a false aneurysm around the aortic root in cases where GRF glue has been used. A residual ascending aorta in a 55-year-old male became a very large false aneurysm during follow up after an acute type A aortic dissection. At the initial operation, the ascending aorta had been replaced with a prosthetic graft and the anastomosis site repaired using gelatin resorcinol formaldehyde (GRF) glue. During the operation, necrosis of the arterial wall was recognized around the proximal anastomosis site between the graft and the native aorta wall. Because of severe adhesion around the native aortic tissue and the left main coronary artery the patient required an aorto-coronary bypass graft and an additional patch reconstruction of the pulmonary artery. Though the operation was very invasive because of the long cardiopulmonary bypass and anoxic arrest, the postoperative course was uneventful. This report highlighted that careful follow up of a false aneurysm formation around an aortic root is needed in cases where GRF glue is used in the initial operation. Surgeons need to be aware of the distinctive complications possible in re-do operations around an aortic root, and take steps to prevent such occurrences.

(Key Words: False aneurysm, Aortic root replacement, Type A dissection, re-do, GRF (gelatin resorcinol-formaldehyde) glue)

Introduction

Early mortality rates from operations for acute type A aortic dissection have improved as a result of recent advances in preoperative recognition, intraoperative techniques, and postoperative surveillance¹⁾²⁾. However, over all 10 year survival after surgical intervention is reported as about 50% to 60%³⁾⁴⁾⁵⁾⁶⁾⁷⁾. The incidence of false aneurysm or redissection after repair of acute type A dissection has been reported and it might be related to the use of gelatin resorcinol-formaldehyde (GRF) glue for tissue necrosis⁸⁾⁹⁾¹⁰⁾¹¹⁾¹²⁾. We report a case of chronic aortic false aneurysm occurring during long-term follow up of an acute aortic dissection.

* Division of Cardiovascular Surgery, Department of Surgery, Jichi Medical University

Case report

A 50-year-old male presented with palpitations and shortness of breath. Medical history included an operation 5 years previously for an acute type A dissection, and another 3 years previously for a chronic descending thoracic aorta aneurysm. After the initial operation, we had recognized a mild aneurismal change around of the aortic root. The patient was followed up with every 6 months with a computed-tomography (CT) scan. On one checkup the aneurysm size showed as having rapidly become larger, with a maximum diameter of 75mm (Fig 1). In both the initial and next operations, histological detection of aorta tissues had been undertaken, but there was no evidence of any cystic medial necrosis in the aorta. As the patient had also presented with a heart murmur because of a ventricular septal defect, we scheduled an elective operation.

The operation was performed in the manner of a cardiovascular re-do; re-exposure was obtained through a re-median sternotomy and cardiopulmonary bypass involving cannulation of the right subclavian artery and right femoral vein was instituted. Inflammatory thickened tissue around the aortic root was found. Under deep hypothermic circulatory arrest, the aorta was opened. There was no defined aortic wall around the ST junction between the prosthetic graft and the valsalva. There was dilatation of the valsalva wall around the non-coronary sinus (Fig. 2). The annulus of the aortic valve was slightly dilated and aortic valves had floppy changes. Very severe adhesion of the pulmonary artery and the posterior aortic wall was recognized. As we had caused some injury to the pulmonary artery at the back of ascending aorta, we repaired the pulmonary artery using bioprosthetic pericardium. Reconstruction of the bilateral coronary orifices necessitated a different method for each; the right coronary orifice was anastomosed using the Carrel Patch method, but this could not be done for the left coronary reconstruction because of severe adhesion around the left coronary orifice. We thus used the Piehler method, which interposes a prosthetic graft between a composite graft and the left coronary. We thus replaced the aortic valve and ascending aorta using a composite graft (aortic valve: ATS #23, Aortic root: GELWEEVE 26mm). The distal side of the graft was anastomosed with the previous prosthetic graft. As it was very difficult to stop the anastomosis bleeding between the graft and left coronary orifice, we carried out left anterior

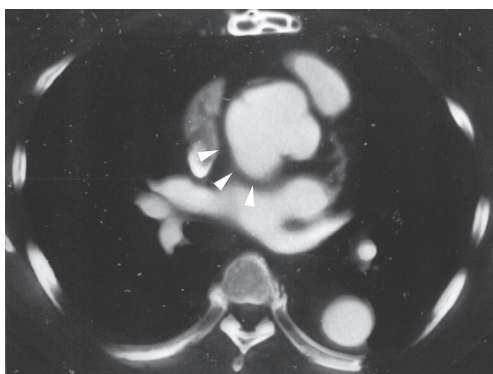


Fig1. Computed tomography scan showing dissecting aneurysm change (arrow) of ascending aorta continuing from non-coronary cusp.

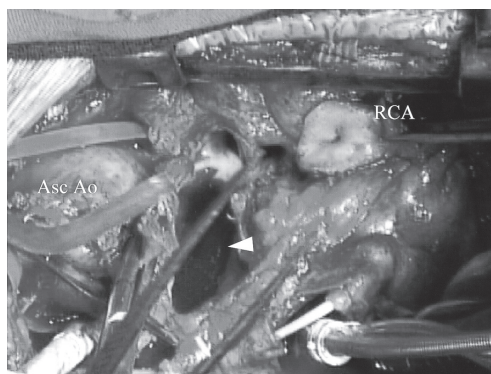


Fig2. The operative picture shows the defect and aneurysm change of aortic wall (arrow) and the destruction around annulus of non-coronary cusp.

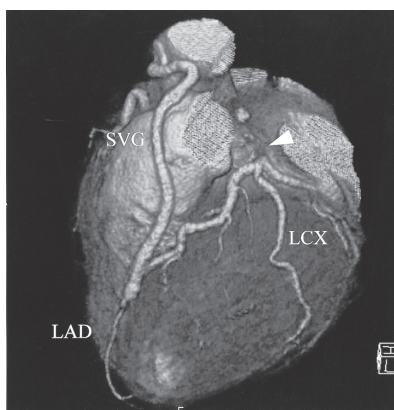


Fig3. Saphenous vein graft (SVG) from aorta to left anterior descending (LAD) artery is patent. Left main trunk is completely occluded (arrow).

descending coronary grafting to the aorta bypass using a saphenous vein graft instead of closing the left coronary orifice. The residual ventricular septal defect was closed directly through the tricuspid valve after aortic root reconstruction. The patient was successfully weaned from cardiopulmonary bypass despite six hundred and thirty-three minute extra corporeal circulation and three hundred minute anoxic cardiac arrest. The post-operative course was uneventful; ultrasound cardiography two weeks after the operation showed good valve function and left ventricular contraction. A dipyridamol loading scintigram for ischemic changes of the cardiac muscle showed no ischemia.

One and half years after the operation a 3-D CT scan of the saphenous vein graft showed that the graft was patent (Fig. 3).

Discussion

Long-term (10-year) survival rates after treatment for acute type A dissection are reported as 30% to 60%^{3) 4) 5) 6) 7)}. One factor that can deteriorate prognosis is re-operation to the residual aorta wall, such as for a false aneurysm or acute redissection^{4) 6) 7)}.

In 1977, Guilmet's group first used Gelatin-resorcinol-formaldehyde (GRF) glue for aortic root reconstruction¹⁴⁾. Since then, GRF glue has been widely used in acute aortic dissections to reinforce the aorta rendered fragile by acute dissection and to strengthen the aortic anastomosis. However, pathological evidence of tissue necrosis because of the toxic effects of the formalin component of the glue used has been reported⁶⁾; with the change of the aortic wall thought to be caused by formaldehyde. After long term follow up cases in which GRF glue was used for acute aortic dissection, cases of re-dissection or an aneurysm change of the necrotic aortic wall tissue have been reported^{8) 9) 12) 13)}.

We used GRF glue for the patient reported here to reinforce the proximal anastomosis side of the dissecting aortic wall in his first operation for acute aortic dissection. There is a high probability that the false aneurysm change in this patient was due to the use of GRF-glue. This was thought to be because in the operative findings the anastomosis site was seen grossly as a deficit of the aortic wall with severe adhesion, and there were no aortic wall tissues in the histological findings. Since this case, we have not used GRF-glue for any aortic dissection operations. For reinforcement of an anastomosis, we stitch dual

felt strips inside and outside of the dissected aorta wall.

The aortic root replacement as a re-do operation remains associated with a high postoperative mortality¹⁵⁾¹⁶⁾. The operative procedure involving an aortic root has various pit-falls, such as injury to cardiovascular systems accompanying with re-median sternotomy, and unplanned coronary artery bypass grafting. In our case, we could open the chest without major injury to the cardiovascular system because we had prepared to establish a right subclavian-femoral cardiopulmonary bypass before sternotomy. However, we failed to expose the aneurysm and reconstruct the coronary orifice because of the severe adhesion due to the use of GRF glue. As a result, we injured the pulmonary artery and the left coronary orifice due to the severe adhesion. We then performed aorto-coronary bypass grafting to make up for being unable to reconstruct the coronary orifice. When aortic root replacement is performed as a second or third cardiac operation, surgeons need to prepare various surgical options for the various possible pit-falls associated with this type of surgery.

References

1. David TE, Armstrong S, Ivanov J et al. Surgery for Acute type A Aortic Dissection. *Ann Thorac Surg* 67: 1999-2001, 1999.
2. Fann JI, Smith JA, Miller DC et al. Surgical management of aortic dissection during a 30-year period. *Circulation* 92 (9 suppl): II 113-121, 1995.
3. Ehrlich MP, Ergin MA, McCullough JN et al. Results of immediate surgical treatment of all acute type A dissections. *Circulation* 102 (19 Suppl 3): III248-III252, 2000.
4. Tan ME, Morshuis WJ, Dossche KM, et al. Long-term results after 27 years of surgical treatment of acute type a aortic dissection. *Ann Thorac Surg* 80(2): 523-529, 2005.
5. Pansini S, Gagliardotto PV, Pompei E et al. Early and late risk factors in surgical treatment of acute type A aortic dissection. *Ann Thorac Surg* 66(3): 779-784, 1998.
6. Sabik JF, Lytle BW, Blackstone EH et al. Long-term effectiveness of operations for ascending aortic dissections. *J Thorac Cardiovasc Surg* 119(5): 946-962, 2000.
7. Casselman FP, Tan ME, Vermuulen FE et al. Durability of aortic valve preservation and root reconstruction in acute type A aortic dissection. *Ann Thorac Surg* 70: 1227-1233, 2000.
8. Kazui T, Washiyama N, Bashar AH et al. Role of biologic glue repair of proximal aortic dissection in the development of early and midterm redissection of the aortic root. *Ann Thorac Surg* 72(2): 509-514, 2001.
9. Suehiro K, Hata T, Yoshitaka H et al. Late aortic root redissection following surgical treatment for acute type A aortic dissection using Gelatin-Resorcin-Formalin glue. *Jpn J Thorac Cardiovasc Surg* 50(5): 195-200, 2002.
10. Bachet J, Goudot B, Dreyus GD, et al. Surgery for acute type A aortic dissection: The Hopital Foch Experience (1977-1998). *Ann Thorac Surg* 67: 2006-2009, 1999.
11. Fukunaga S, Karck M, Harringer W, et al. The use of gelatin-resorcin-formalin glue in acute aortic dissection type A. *Europ J Cardio-thorac Surg* 15: 564-570, 1999.
12. Kamada T, Nakajima T, Izumoto H, et al. Late complications following surgery for type A acute aortic dissection using gelatin resorcin formaldehyde glue: report of two cases. *Surgery Today* 35: 996-999, 2005.

13. Suzuki S, Imoto K, Uchida K, et al. Aortic root necrosis aftersurgical treatment using gelatin-resorcinol formaldehyde (GRF) glue in patients with acute type A aortic dissection. *Ann Thorac Cardiovasc Surg* 12: 333-340, 2006
14. Guilmet D, Bachet J, Goudot B, et al. Use of biological glue in acute aortic dissection. Preliminary clinical results with a new surgical technique. *J Thorac Cardiovasc Surg* 77: 516-522, 1979.
15. Hahn C, Tam SK, Vlahakes GJ, et al. Repeat aortic root replacement. *Ann Thorac Surg* 66: 88-91, 1998.
16. Girardi LN, Krieger KH, Mack CA, et al. Reoperations on the ascending aorta and aortic root in patients with previous cardiac surgery. *Ann Thorac Surg* 82: 1407-1412, 2006.

急性大動脈解離手術時に使用した GRF 糊が原因と考えられる遠隔期基部大動脈仮性瘤の一例

坂野 康人*, 齊藤 力*, 三澤 吉雄*

要 約

A型急性大動脈解離の遠隔期に大動脈基部の拡大を呈する症例が知られており、初回手術時に断端形成に用いられた GRF 糊とホルマリン毒性との関与が示唆されている。症例は50才男性、大動脈基部が最大径75mmに拡大し手術適応となる。5年前のA型急性大動脈解離手術時において大動脈解離の修復に GRF 糊を使用。今回術中所見では大動脈基部の前回吻合部分が壊死しており、大動脈壁組織が一部欠損して仮性瘤となっていた。大動脈基部置換術を施行したが大動脈後面と左冠動脈周辺および肺動脈の癒

着が強く、左冠動脈起始部を閉鎖し冠動脈バイパス術を追加した。肺動脈の損傷部位の修復も必要であった。術後経過は良好であった。急性大動脈解離などで初回手術に GRF 糊を使用した症例は遠隔期に仮性瘤を来すことがあり注意深いフォローアップが必要になる。また大動脈基部における再手術は周囲組織が強固に癒着しており剥離操作には注意を要する。

(キーワード：仮性大動脈瘤，大動脈基部置換術，A型急性大動脈解離，再手術，GRF 糊)