

Original Article

Intracellular staining of granzyme B and perforin for diagnosis of acute graft-versus-host disease

Haruko Matsu, Katsutoshi Ozaki, Raine Tatara, Satoko Oka,
Akiko Meguro, Iekuni Oh, Kazuya Sato, Keiko Hatanaka,
Masaki Mori, Kazuo Muroi, and Keiya Ozawa

Abstract

Acute graft-versus-host disease (aGVHD) is diagnosed based on clinical manifestations and bilirubin levels. Pathological survey is recommended but time-consuming and usually becomes available only after treatment. Thus, an aGVHD-specific maker that could be measured within a day is highly desirable for diagnosis. Reverse transcription-polymerase chain reaction for cytotoxic molecules, such as granzyme B and perforin, has been reported to be useful in the diagnosis of aGVHD; however, the significance of these markers has not yet been established. Here, we re-evaluated these molecules using intracellular staining and demonstrated that they are correlated with clinical grade of aGVHD, and that they decrease after improvement. These markers might therefore be practical due to the simplicity and rapidity of measurement.

(Key words: GVHD, granzyme B, perforin)

Introduction

Acute graft-versus-host disease (aGVHD) is a major complication after hematopoietic stem cell transplantation (HSCT)^[1,2] and a diagnosis of aGVHD is based on clinical manifestations^[3]. However, the lack of a specific, scientific and assessable marker has been problematic in clinical practice. Evidence supporting a diagnosis of aGVHD may be obtained from biopsy samples from the skin, liver or gastrointestinal tract, but it is not specific for aGVHD^[4,5], while pathological findings usually become available after steroid therapy. It is thus clear that a rapidly measurable marker is useful and desirable for diagnosis of aGVHD.

The importance of cytotoxic molecules in aGVHD has been established in studies using gene-deficient mice^[6-8]. In this study, we focused on the expression levels of cytotoxic molecules, such as granzyme B and perforin, as a correlation between the expression levels of such molecules and aGVHD has been suggested by quantitative reverse transcription-polymerase chain reaction (RT-PCR)^[9,10]. To rapidly obtain data on these candidate aGVHD markers, we re-evaluated the feasibility of monitoring these molecules by intracellular staining.

Materials and Methods

Patients

Patients underwent HSCT between 2006 and 2008 at Jichi Medical University. They provided written informed consent for samples to be taken under the protocol approved by the Intramural Review Board (eki 06-07).

Intracellular staining

Around two weeks after HSCT, when we recognized a recovery of WBC count, blood samples were obtained and analyzed within 12 hours, and thereafter it repeated every week.

Antibodies against CD8, CD56, CD4, CD19, granzyme B and perforin were purchased from eBioscience (San Diego, CA) and BD Biosciences (San Jose, CA). Intracellular staining was performed with Cytofix, Cytoperm solution (BD Biosciences) **in accordance with the manufacturer's instructions**. Analysis was performed using an LSR (BD Biosciences) and the data were analyzed using CellQuest (BD Biosciences) software.

Statistical analysis

Student's t-test was used and $P < 0.05$ was considered to be significant.

Results

Here, we investigated the expression levels of the cytotoxic molecules granzyme B and perforin using peripheral blood mononuclear cells from 15 patients who underwent allogeneic HSCT at our institution, and found that these markers are upregulated in patients with aGVHD. Median age of patients was 40 years and related- and unrelated-HSCT accounted for 33% and 66% of cases, respectively (**Table I**). GVHD prophylaxis was short-term methotrexate and cyclosporin or tacrolimus. Patients with grade II-IV aGVHD (those needing treatment) had a higher positive percentage of granzyme B or perforin, whereas patients with grade 0-I aGVHD (no treatment) had a lower positive percentage (**Figure 1A**). The difference was statistically significant for granzyme B ($p=0.0055$), but not perforin ($p=0.12$), despite the similar trends. After the therapy with first-line steroid and second-line immunosuppressive reagents, such as mycophenolate mofetil (MMF) and infliximab, the positive percentage of granzyme B and perforin decreased, suggesting a relationship with the activity of aGVHD (**Figure 1B**). Staining with CD8 and CD56 suggested that a significant proportion of granzyme B- or perforin-positive cells were either CD8⁺ T cells (**Figure 1C**) or CD56⁺ NK cells (**data not shown**). In healthy controls, the percentages of cytotoxic molecules positive cells in peripheral blood were less than 20%, whereas in patients with grade 0-I and grade II-IV aGVHD, those were 22% and 60%, respectively (**Figure 1C and 1A**). Absolute numbers of CD8, CD56, CD8/granzyme B, CD8/perforin, CD56/granzyme B, and CD56/perforin cells were variable and showed no correlation with the severity of aGVHD.

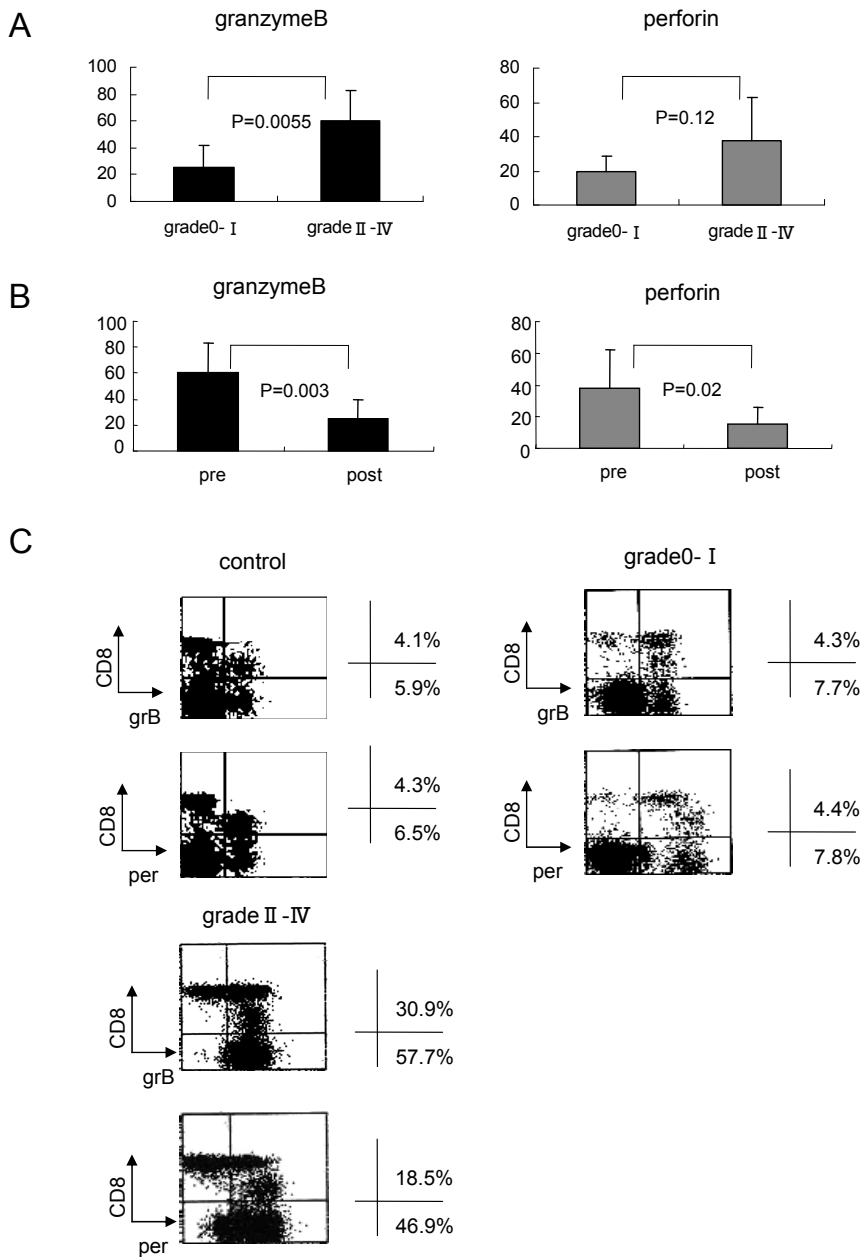
Table I. Patient characteristics.

Patient	Age	Sex	Diagnosis	Transplant	GVHD grade
1	23	M	Ph+ ALL, 1st CR	unrelated BMT	II
2	37	M	NK cell leukemia/lymphoma, PR	unrelated BMT	II
3	42	M	MDS overt leukemia, NR	sibling PBSCT	III
4	38	M	AML(M4Eo), 2nd CR	unrelated BMT	0
5	29	M	AML(M1), 1st CR	unrelated BMT	II
6	60	F	AML with TLD, NR	sibling BMT	III
7	33	M	AML(M1), 1st CR	unrelated BMT	II
8	60	M	FL, Secondary MDS	unrelated BMT	II
9	25	F	AML(M2), NR	unrelated BMT	0
10	27	F	AML(M2), NR	sibling PBSCT	II
11	48	F	FL(bulky), PD	sibling PBSCT(RIST)	0
12	49	M	AML(M2), 1st CR	sibling BMT	0
13	38	M	PTCL, PR	unrelated BMT(RIST)	II
14	60	F	AML(M2), NR	unrelated BMT	IV
15	36	M	AML(M5a), NR	unrelated BMT	I

Sources of stem cells are listed on the right. Unrelated and related transplantations accounted for 66% and 33% of cases, respectively. Ph, Philadelphia chromosome; ALL, acute lymphoblastic leukemia; AML, acute myeloid leukemia; MDS, myelodysplastic syndrome; CR, complete remission; PR, partial response; NR, no response; FL, follicular lymphoma; PTCL, peripheral T-cell lymphoma; PD, progressive disease; RIST, reduced intensity stem cell transplantation; PBSCT, peripheral blood stem cell transplantation.

Figure legends

Figure 1. Expression of granzyme B and perforin. (A) Comparison between expression levels in patients with grade II-IV aGVHD and those with grade 0-I aGVHD. Student's t-test was utilized to determine p-values. (B) Comparison of expression levels between pre-treatment and post-treatment for aGVHD. Post-treatment was defined as a week after the first day of treatment. Student's t-test was utilized to determine p-values. (C) Typical flow cytometric appearance (dot blots) of peripheral blood cells from a healthy control, a patient with grade 0-I aGVHD, and a patient with grade II-IV aGVHD.



Discussion

After allogeneic HSCT, peripheral blood mononuclear cells from patient were subjected to intracellular staining and flow cytometric analysis. This method allows results to be obtained within one day. Thus, one can begin steroid therapy soon after evaluation. When clinical manifestations are sufficient to begin steroid therapy, testing may be omitted, but when manifestations are insufficient, the results of intracellular staining for granzyme B and perforin may be helpful for decisions regarding diagnosis and treatment. We would propose that it might be a good surrogate marker for a patient with gastrointestinal aGVHD without other symptoms. In fact, two patients were suspected as the disease in this study. In these cases, results of our tests were predictable for the requirement of steroid therapy. However, unfortunately, we could not argue strongly because of the limited number of patients.

The proportion of granzyme B positive cells in peripheral blood was correlated to the severity of GVHD (**Fig. 1A**) but the absolute number was not, as described in Results. This was mainly due to the varied number of peripheral white blood cells in each patient. As they were in recovery phase when we performed analysis, the numbers were so various.

Even in patients without significant aGVHD (two of six cases with grade 0-I aGVHD), the expression of granzyme B and perforin was upregulated. In one case, this may have been related to CMV infection, as the patient was positive for CMV antigenemia without any symptoms. The other patient did not show any symptoms of infectious disease or aGVHD. Both aGVHD and infectious disease can activate T cells. In fact, CMV infection is reported to be correlated with upregulated cytotoxic molecules in some cases^[2]. Although false positives may be a problem in this assay, infectious diseases can be usually distinguished from aGVHD by other makers, such as CRP and CMV antigenemia. Moreover, the timing of CMV infection is usually several weeks later than that of aGVHD. Granzyme B and perforin have been already investigated in the field of GVHD^[1,2] and these studies assessed the level of expression of granzyme B and perforin by RT-PCR. Using our method, expression levels of those molecules can be measured as protein and the results can be obtained within a day. This may help in the timely diagnosis of aGVHD and may be simpler and more rapid than RT-PCR-based methods. In clinical practice, however, it would be most practical to measure the expression of granzyme B and perforin only when aGVHD is suspected.

In summary, intracellular staining of granzyme B and perforin may be a helpful surrogate marker in the diagnosis of aGVHD, especially for a patient with gastrointestinal aGVHD without other symptoms.

Acknowledgments

This work was supported in part by grants from the Ministry of Health, Labor and Welfare of Japan, by Grants-in-Aid for Scientific Research from the Ministry of Education, Culture, Sports, Science and Technology of Japan.

References

1. Couriel D, Caldera H, Komanduri K, et al. Acute graft-versus-host disease: pathophysiology, clinical manifestations, and management. *Cancer*. 2004; 101: 1936-1946.
2. Jacobsohn DA, Vogelsang GB. Acute graft versus host disease. *Orphanet J Rare Dis*. 2007; 2: 35
3. Przepiorka D, Weisdorf D, Martin P, et al. 1994 Consensus Conference on Acute GVHD Grading. *Bone Marrow Transplant*. 1995; 15: 825-828.

4. Esteban JM, Somlo G. Skin biopsy in allogeneic and autologous bone marrow transplant patients: a histologic and immunohistochemical study and review of the literature. *Mod Pathol.* 1995; 8: 59-64.
5. Kuykendall TD, Smoller BR. Lack of specificity in skin biopsy specimens to assess for acute graft-versus-host disease in initial 3 weeks after bone-marrow transplantation. *J Am Acad Dermatol.* 2003; 49: 1081-1085.
6. Braun MY, Lowin B, Tschopp J, et al. Cytotoxic T cells deficient in both functional fas ligand and perforin show residual cytolytic activity yet lose their capacity to induce lethal acute graft-versus-host disease. *J Exp Med.* 1996; 183: 657-661.
7. Baker MB, Altman NH, Levy RB, et al. The role of cell-mediated cytotoxicity in acute GVHD after MHC-matched allogeneic bone marrow transplantation in mice. *J Exp Med.* 1996; 183: 2645-2656.
8. Graubert TA, Russell JH, Ley TJ. The role of granzyme B in murine models of acute graft-versus-host disease and graft rejection. *Blood.* 1996; 87: 1232-1237.
9. Jaksch M, Remberger M, Mattsson J. Increased immune transcript levels are correlated with acute graft-versus-host disease and cytomegalovirus response after allogeneic stem cell transplantation. *Transplantation.* 2004; 77: 195-200.
10. Jaksch M, Uzunel M, Mattsson J, et al. Increased levels of immune transcript in patients with acute GVHD after allogeneic stem cell transplantation. *Bone Marrow Transplant.* 2003; 31: 183-190

急性 GVHD の補助的検査： granzyme B および perforin 細胞内染色の有用性

松 春子, 尾崎 勝俊, 目黒 明子, 畑中 恵子,
多々良礼音, 翁 家国, 佐藤 一也, 森 政樹,
室井 一男, 永井 正, 小澤 敬也

要 約

移植片対宿主病 (Graft versus host disease: GVHD) の診断治療は, 移植成績を左右する重要な因子である。日常診療において GVHD の診断は主に臨床症状に頼っており, 診断のよりどころとなる科学的根拠の病理検査は結果が判明するまでに時間を要する。今回, GVHD が疑われた場合に当日に結果が判明する検査とし

て, 末梢血の granzyme B, perforin の細胞内染色を施行した。臨床的に GVHD を認めた群では granzyme B, perforin の陽性率が高く, 治療後に減少を認めた。今回用いたフローサイトメトリーによる解析は簡便であり, 当日に結果が判明することから, 急性 GVHD の診断に補助的役割を果たす可能性がある。