

Research Report

A Pilot Study of A Novel Therapy Using Mesenchymal Stromal Cells for Steroid-Resistant Graft-Versus-Host Disease

Kazuya Sato¹⁾, Kazuo Muroi¹⁾, Satoko Oka²⁾, Miyuki Sasazaki¹⁾,
Rie Hosonuma¹⁾, Katsutoshi Ozaki¹⁾, Shin-ichiro Fujiwara¹⁾, Iekuni Oh¹⁾,
Tomohiro Matsuyama¹⁾, Ken Ohmine¹⁾, Takahiro Suzuki¹⁾, Masaki Mori¹⁾,
Tadashi Nagai¹⁾ and Keiya Ozawa¹⁾

Abstract

Mesenchymal stromal cells (MSCs) have been reported to have immunomodulatory effects and ameliorate severe graft-versus-host disease (GVHD) after allogeneic stem cell transplantation (SCT). We have conducted a pilot study using human MSCs for the treatment of steroid-resistant GVHD. Between January 2006 and December 2010, 10 patients (7 males and 3 females) with a median age of 37.9 years (range: 23-65 years) who had steroid-resistant GVHD were enrolled in this study. MSCs were isolated from bone marrow of the patient's relatives. Among these 10 patients, three were treated with MSCs. The other seven did not receive MSC treatment because of an improvement in GVHD due to the addition of immunosuppressants including methylprednisolone, spontaneous GVHD regression, or early death. Of the three patients treated with MSCs, one showed an improvement in his intestinal GVHD, another showed no change in his intestinal GVHD and third had his dose of prednisolone successfully decreased without progression of his intestinal GVHD. No immediate adverse reactions associated with MSC infusions were observed. Since the present study was limited to a small number of patients, it is difficult to evaluate the efficacy of MSCs for steroid-resistant GVHD. Further investigations are needed to establish the clinical application of MSCs for steroid-resistant GVHD.

(Keywords: mesenchymal stromal cells, graft-versus-host disease, stem cell transplantation)

Introduction

Allogeneic stem cell transplantation (SCT) is a potentially curative therapy for a variety of malignant or non-malignant hematological diseases. Recently, the use of allogeneic SCT for elderly patients with a poor general status has been expanding because of the development of reduced-intensity (non-myeloablative) conditioning regimens, pre-treatment immune suppression protocols (graft-versus-host disease prophylaxis) and the prevention and treatment of severe infections¹⁾. These dramatic advance-

1) Division of Hematology, Jichi Medical University, Tochigi, Japan

2) First Department of Internal Medicine, Osaka Medical College, Osaka, Japan

ments have allowed allogeneic SCT to be carried out with less toxicity and complications in patients who were not considered to be candidates for a conventional transplant. However, graft-versus-host disease (GVHD) can still cause life-threatening complications¹⁻⁴. The widespread use of peripheral blood stem cell transplantation, which is known to achieve a more rapid engraftment than other stem cell sources, has resulted in a higher incidence of GVHD⁵. Reduced-intensity conditioning SCT may be associated with a decreased incidence of GVHD compared with conventional transplantation, although the relapse rate is significantly higher in the former setting. T-cell-depleted allogeneic SCT or the prophylactic use of strong immunosuppressive agents reduces the risk of GVHD but also increases the relapse rate.

Mesenchymal stromal cells (MSCs) have been found to suppress the proliferation of activated T-cells *in vitro*, suggesting that they represent a novel cell therapy for severe GVHD^{6,9}. In a multicenter phase II study by the European Group for Blood and Marrow Transplantation (EBMT), the response rate for MSC therapy in case of steroid-resistant GVHD was over 70% and the response did not depend on HLA compatibility between patients and MSC donors⁸. We report a pilot study of the treatment of patients with steroid-resistant GVHD after allogeneic SCT with MSCs.

Patients and methods

Approval was obtained from the institutional review board at Jichi Medical University for the administration of human MSCs to patients with steroid-resistant GVHD after allogeneic SCT (Jichi Medical University 05-63, approved on January 16, 2006). The purpose of this study was to clarify whether human MSCs suppress steroid-resistant acute GVHD. The number of patients was not established. All participants provided written informed consent prior to the beginning of the study. Eligibility criteria were as follows: patients must have steroid-resistant GVHD, not be in relapse after allogeneic SCT, and have neither consciousness disturbance nor severe infections. Primary hematological disease status, stem cell donor (related or unrelated), stem cell source (bone marrow, peripheral blood stem cells or cord blood), HLA compatibility and GVHD prophylaxis were not regulated. Steroid-resistant GVHD was defined as the progression or persistence of GVHD 7 days after the administration of standard-dose (1-2mg/kg/day) prednisolone (PSL)¹⁰ or GVHD recurrence during steroid tapering. All patients received standard GVHD prophylaxis consisting of either cyclosporine or tacrolimus with short-term methotrexate (MTX) treatment. GVHD severity was graded on the basis of the revised Glucksberg criteria¹¹. Eligible MSC donors were healthy individuals of 20 to 60 years old who did not suffer from liver, renal, or heart dysfunction, or severe infections. A history of malignancy and allergic reactions to anesthetic agents were excluded from the MSC donor criteria. MSC donors were limited to the patient's relatives including the person who donated his or her hemopoietic stem cells to the patient.

Bone marrow (BM) aspirates (10 ml) were taken from the iliac crests of the healthy donors, and resuspended in phosphate-buffered saline. Human BM MSCs were isolated as described previously¹². Briefly, BM mononuclear cells were separated by centrifugation on Ficoll-Conray density gradients. Red blood cells were removed by ammonium chloride lysis. Washed cells were then resuspended in optimized human MSC culture medium and plated at a density of 1.0×10^6 /ml in 175 cm² flasks. The cultures were maintained at 37°C in a humidified atmosphere containing 5% CO₂ for up to 6 weeks. MSCs were then harvested during or before the fourth passage. The targeted number of MSCs was 1×10^6 cells/patient body weight (kg). Neither the frequency of MSC administration nor the interval between MSC

administrations was defined. The purity of harvested MSCs as well as the quality of the cells such as antigen expression profiles and T-cell-suppressing abilities was not determined. The MSC culture supernatant was checked for bacteria, fungi, and endotoxin contamination. Tests for human herpes virus 6, Epstein-Barr virus, and cytomegalovirus DNA were performed using the reverse transcription-polymerase chain reaction. Obtained MSCs were cryopreserved in certain cases. Chemirism examinations to detect infused MSCs after the infusion of the cells were not performed.

Results

Between January 2006 and December 2010, 10 patients (7 males and 3 females) with a median age of 37.9 (range: 23-65) who had steroid-resistant GVHD enrolled in this study. The characteristics of the patients are listed in Table 1. Before allogeneic SCT, patients received either myeloablative (n=7) or reduced-intensity (n=3, cases 4, 6, and 10) conditioning. To obtain sufficient number of MSCs ($1.0-2.0 \times 10^6$ cells/kg), we required BM aspirates from 12 healthy donors because the initial number of mononuclear cells was insufficient (n=1) and the expected required cell number was not acquired by the fourth passage (n=1). The characteristics of 10 MSC donors are shown in Table 2. Among the 10 patients, three (cases 3, 9, and 10) were treated with MSCs. The other seven patients did not receive MSCs because of an improvement in GVHD due to the addition of immunosuppressants including methylprednisolone (mPSL), spontaneous GVHD regression, or early death. A short summary of the three patients who received MSCs is described below.

Table 1 Characteristics of the patients with steroid-resistant acute GVHD after stem cell transplantation

	Age/Gender	Diagnosis	Disease status	Stem cell donor/Source	GVHD prophylaxis	GVHD grading	GVHD treatment	Outcome
1	31y/M	CML	CP	Sibling/BM	FK506+MTX	II	FK506, PSL, mPSL, MMF	Alive, 57M
2	23y/M	ALL	CR	Matched unrelated/BM	FK506+MTX	II	FK506, PSL, MMF	Death (relapse)
3	42y/M	MDS-leukemia	NR	Sibling/PB	CyA+MTX	III	CyA, FK506, PSL, mPSL, MMF, infliximab	Death (sepsis)
4	60y/M	MDS-leukemia	NR	HLA-mismatched Unrelated/BM	CyA+MTX	III	FK506, PSL, MMF	Death (pneumonia)
5	27y/M	MDS-leukemia	NR	Sibling/PB	CyA+MTX	II	CyA, PSL, MMF	Death (sepsis)
6	24y/F	AML	NR	HLA-mismatched Unrelated/CB	FK506+MTX	II	FK506, PSL	Death (relapse)
7	34y/F	MDS	NR	Sibling/PB	CyA+MTX	II	CyA, PSL	Alive, 32M
8	31y/F	AML	CR	Matched unrelated/BM	FK506+MTX	II	FK506, PSL	Death (relapse)
9	33y/M	AML	CR	HLA-mismatched unrelated/BM	FK506+MTX	IV	FK506, PSL, mPSL, MMF, ATG, infliximab	Death (GVHD)
10	65y/M	NHL	PR	Matched unrelated/BM	FK506+MTX	III	FK506, PSL, mPSL, MMF, infliximab	Alive, 12M

CML, chronic myeloid leukemia; ALL, acute lymphoid leukemia; AML, acute myeloid leukemia; MDS, myelodysplastic syndrome; MDS-leukemia; AML developed from MDS; NHL, non-Hodgkin lymphoma; CP, chronic phase; CR, complete remission; PR, partial remission; NR, no remission; BM, bone marrow; PB, peripheral blood stem cells; CB, cord blood; CyA, cyclosporine; FK506, tacrolimus; MTX, methotrexate; PSL, prednisolone; mPSL, methylprednisolone; MMF, mycophenolate mofetil; ATG, anti-thymocyte globulin; y, years; M, male; F, female; M, month.

Table 2 Details of MSC donors and MSC infusion

Patient no.	MSC donor	MSC infusion (Y/N)	The number of MSC infusions	The number of infused MSCs per patient body weight (Kg)
1	Cousin	N	ND	ND
2	Sister	N	ND	ND
3	Cousin	Y	Twice	1st, 0.06x10 ⁶ cells/kg; 2nd, 0.91x10 ⁶ /kg
4	Son	N	ND	ND
5	The same donor#	N	ND	ND
6	Mother	N	ND	ND
7	The same donor#	N	ND	ND
8	Brother	N	ND	ND
9	Sister	Y	Twice	1st, 1.1x10 ⁶ /kg; 2nd, 1.1x10 ⁶ /kg
10	nephew	Y	Once	0.83x10 ⁶ /kg

MSC, mesenchymal stromal cell; Y, yes; N, no; ND, not done; #, The MSC donor is identical to the person who donated hemopoietic stem cells.

The detailed clinical course of case 3 (a 42-year-old male) including a figure was previously reported¹³. Briefly, the patient was diagnosed as having acute myeloid leukemia (AML) that progressed from myelodysplastic syndrome. He received an allogeneic PBSC transplant from his HLA-identical sister on May 1, 2007, after a conventional conditioning regimen consisting of total body irradiation (TBI) and cyclophosphamide (CY). GVHD prophylaxis was short-term MTX and cyclosporine. He developed diarrhea, abdominal pain, liver dysfunction (total bilirubin: 2.0 mg/dl), and skin eruptions on day 15. The patient was diagnosed as having grade III GVHD and a dose of 1.0 mg/kg/day of PSL as the primary treatment was given. By day 22, the patient developed severe intestinal GVHD despite the administration of mycophenolate mofetil (MMF) in addition to an increased dose of PSL (2.0 mg/kg/day). He received a further bolus of mPSL and tacrolimus instead of cyclosporine, however, his intestinal symptoms persisted. A colonoscopy on day 48 showed edema, erosion and bleeding in the colon mucosa and villus atrophy in the end portion of the ileum. The histological examination of the biopsy specimens obtained from the colon showed a decrease in cryptic glands and interstitial edema but no massive cell infiltration in the interstitial areas or marked apoptosis in the epithelial cells, indicating a state after chronic mucosal damage caused by GVHD. He was treated with MSCs derived from his cousin on days 58 (0.06x10⁶/kg/day) and 79 (0.91x10⁶/kg/day), and then, his abdominal symptoms gradually improved. A colonoscopy performed 14 days after the first MSC infusion showed a slight improvement in the above abnormal findings in the colon mucosa. Immediate adverse reactions associated with MSC infusions were not observed. He received infliximab (10 mg/kg/day) on days 134 and 153 because of the persistent intestinal GVHD. The patient was discharged on day 181, i.e., 10 weeks after the second MSC infusion, however, he was re-admitted 8 days later because of sepsis caused by staphylococcus epidermidis. On re-admission, he had been given tacrolimus (1 mg/day), PSL (0.6 mg/kg/day, i.e., 40 mg/kg) and MMF (1.5 g/day). Although he received intensive treatment with antibiotics, he died 2 days later.

A 33-year-old male (case 9), who was diagnosed with AML-M0 according to the French-American-British classification in complete remission, received an allogeneic BM transplant from an HLA two-allele mismatched unrelated donor on March 6, 2009. The conditioning was a conventional regimen of TBI and CY. GVHD prophylaxis was short-term MTX and tacrolimus. The patient developed a skin eruption on day 16 and was treated with a dose of 1.3 mg/kg/day (80 mg/day) of mPSL (Figure 1). However, he developed acute pancreatitis and the steroid therapy was ceased. Thereafter, he complained of severe

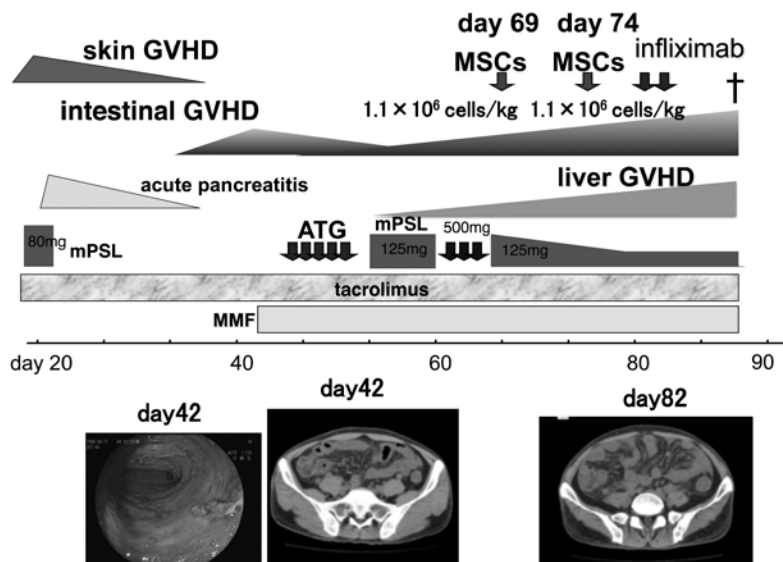


Figure 1 The clinical course of case 9.

MSCs, mesenchymal stromal cells; mPSL, methylprednisolone; ATG, anti-thymocyte globulin; MMF, mycophenolate mofetil; GVHD, graft-versus-host disease. The colonoscopic image indicates colon mucosa.

abdominal pain with bloody diarrhea. On day 42, a colonoscopy showed diffuse mucosal edema with cobblestone-like changes consistent with gastrointestinal GVHD. Intestinal GVHD was confirmed by the histological examination of biopsy specimens obtained from the colon. Overall GVHD grade was estimated as IV. To suppress intestinal GVHD, MMF, ATG and a bolus of mPSL were given, however, these treatments did not resolve the intestinal GVHD and liver GVHD appeared. MSCs were prepared from his sister. He received a dose of 1.1×10^6 MSCs/kg/day on days 69 and 74, followed by a dose of 5 mg/kg/day of infliximab twice¹⁴⁾. No immediate adverse reactions associated with the MSC infusions were observed. Unfortunately, none of these treatments neither resolved the intestinal GVHD or liver GVHD. The patient died of GVHD and multiple organ failure on day 88.

A 65-year-old male (case 10) with stage IV mantle cell lymphoma relapsed after autologous PBSC transplantation. The patient underwent allogeneic BM transplantation from a HLA-identical unrelated donor on March 17, 2010, after reduced intensity conditioning consisting of fludarabine, busulfan and low-dose TBI. GVHD prophylaxis was short-term MTX and tacrolimus. On day 14, watery diarrhea appeared. On day 22, a colonoscopy showed redness in the rectum mucosa. Histological findings of biopsy specimens obtained from the colon showed apoptotic bodies in the crypt glands and interstitial lymphocyte infiltration in the colon mucosa, consistent with GVHD. He received a dose of 2 mg/kg/day of PSL in addition to tacrolimus. Then, his watery diarrhea gradually disappeared. He discharged on day 83, at which time he received a dose of 0.3 mg/kg/day (15 mg/day) of PSL and 2.4 mg/day of tacrolimus. On day 100, he was re-admitted because of severe watery diarrhea and appetite loss (Figure 2). A colonoscopy on day 105 showed edema, redness and white mucus in the colon mucosa and villous atrophy in the

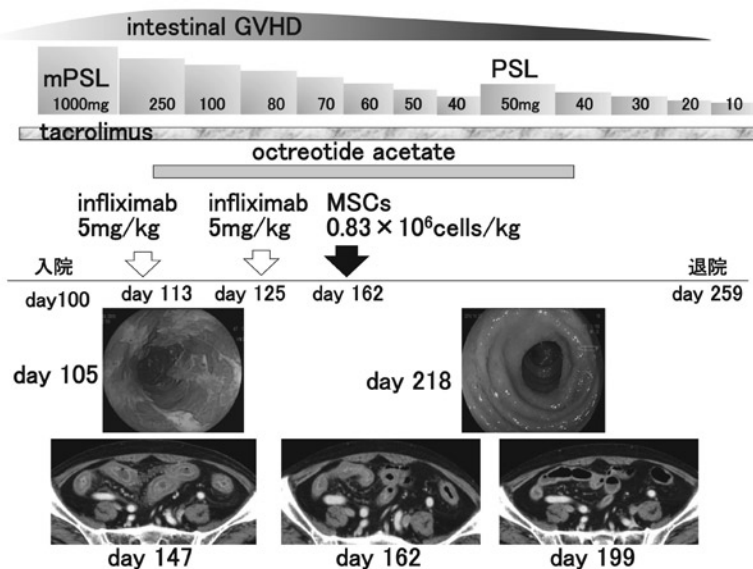


Figure 2 The clinical course of case 10.

MSCs, mesenchymal stromal cells; mPSL, methylprednisolone; PSL, prednisolone; GVHD, graft-versus-host disease. The two colonoscopic images indicate colon mucosa.

end portion of the ileum. A computed tomography scan on day 147 showed edematous change in the colon. The histological examination of biopsy specimens obtained from the colon showed gland apoptosis and interstitial lymphocytic infiltration, consistent with intestinal GVHD. Overall GVHD grade was III. He received a bolus of mPSL (1000 mg/day) for 3 days, a dose of 5 mg/kg/day of infliximab twice and a dose of 300 μ g/day of octreotide in addition to tacrolimus. Attempts were made to prepare MSCs from his two daughters' BM, however, the cells grew slowly and adequate numbers of MSCs to infuse were not obtained. MSCs from his nephew were rapidly grown and were given (0.83×10^6 /kg) on day 159. No immediate adverse reactions associated with the MSC infusion were observed. These combination therapies resolved his GVHD. The PSL dose was gradually decreased from 1.0 mg/kg/day (50 mg/day) on the infusion of MSCs to 0.2 mg/kg/day (10 mg/day) without GVHD progression. He was discharged on day 259. Thereafter, he was hospitalized because of infection. Now he attends to the Outpatient Department of our hospital. Although he has no diarrhea, he receives intravenous rehydration three times a week because of insufficient intake. The immunosuppressants which he receives are a dose of 0.5 mg/day of tacrolimus, 2 mg/day of PSL and 500 mg/day of MMF.

Discussion

We experienced 10 patients with steroid-resistant GVHD who were treated with ($n=3$) or without ($n=7$) MSCs for 5 years. Unfortunately, seven of the ten patients who showed steroid-resistant GVHD (70%) died, due to relapse ($n=3$), severe infection ($n=3$) associated with GVHD treatment and uncontrollable GVHD ($n=1$), suggesting that the current strategy for treating steroid-resistant GVHD fol-

lowing allogeneic SCT is not satisfactory. Initial treatment with corticosteroids remains the standard approach for acute GVHD, however, the outcome for patients who do not respond to corticosteroids is poor, with a survival rate at 2 years of only about 10%¹⁵. There is no established standard therapeutic strategy for steroid-resistant GVHD. Therefore, the development of a novel alternative therapy that is both specific and less toxic for steroid-resistant GVHD is essential.

In the study by the EBMT, no patients suffered from immediate or late adverse effects after MSC infusions⁶. The response rates of MSC infusions to patients with GVHD are reported to not be correlated with age, HLA-match status between the MSC donor and the recipient, GVHD severity (the response in patients with grade II-III acute GVHD was similar to that in patients with grade IV GVHD) or the number of MSCs (median dose: 1.4×10^6 , range: 0.4 to 9.0×10^6 cells/kg)⁶. Interestingly, children responded better than adults, although the statistical power of these findings was insufficient because of the low number of patients⁶. In order to decide an adequate cell dose, a prospective randomized trial was performed: patients with grade II-IV GVHD had an equal probability of receiving either high-dose (8.0×10^6 cells/kg) or low-dose (2.0×10^6 cells/kg) MSCs¹⁶. There were no differences in safety or efficacy between the high and low MSC doses. Interestingly, a higher response rate (89%) was observed in the patients with gastrointestinal GVHD¹⁶.

We used MSCs at low passages (four passages or less) in this study. MSCs have been reported to be able to undergo many *in vitro* passages¹⁷, although they change their morphology from spindle-shaped fibroblastic cells to very large and flat cells during prolonged culture, as reported previously^{18,19}. As multiple passages of MSCs may lead to chromosomal modification and loss of function of the cells, the consensus is that MSCs should be used at lower passages for cell therapy¹⁸⁻²⁰.

There are still some controversies regarding the clinical effectiveness of MSC treatment. In a study by the EBMT, a single dose produced clinically beneficial effects in more than half of patients. Higher response rates were obtained in smaller European studies (case reports or small-scale clinical trials)⁶⁻⁸. In contrast, another group reported that only two of 13 patients (15%) responded to MSCs and that 11 patients required additional salvage immunosuppressive therapy concomitant with further MSC infusions²¹. Furthermore, in a mouse GVHD model, MSCs were able to suppress lymphocyte proliferation *in vitro* but failed to prevent GVHD following allogeneic SCT under a variety of conditions²². We need more accurate and detailed information from both *in vitro* and *in vivo* studies to establish safe and effective MSC treatment methods before the widespread clinical application of MSCs.

References

- 1) Deeg HJ and Sandmaier BM: Who is fit for allogeneic transplantation? *Blood* 116: 4762-4770, 2010.
- 2) Schmitz N, Eapen M, Horowitz MM et al.: Long-term outcome of patients given transplants of mobilized blood or bone marrow: a report from the international Bone Marrow Transplant Registry and the European Group for Blood and Marrow Transplantation. *Blood* 108: 4288-4290, 2006.
- 3) Ringdén O, Karlsson H, Olsson R et al.: The allogeneic graft-versus-cancer effect. *Br J Haematol* 147: 614-633, 2009.
- 4) Mielcarek M and Storb R: Graft-vs-host disease after non-myeloablative hematopoietic cell transplantation. *Leuk Lymphoma* 46: 1251-1260, 2005.
- 5) Stem Cell Trialists' Collaborative Group: Allogeneic peripheral blood stem-cell compared with bone

- marrow transplantation in the management of hematologic malignancies: an individual patient data meta-analysis of nine randomized trials. *J Clin Oncol* 23: 5074-5087, 2005.
- 6) Le Blanc K, Rasmusson I, Sundberg B et al.: Treatment of severe acute graft-versus-host disease with third party haploidentical mesenchymal stem cells. *Lancet* 363: 1439-1441, 2004.
 - 7) Ringdén O, Uzunel M, Rasmusson I et al.: Mesenchymal stem cells for treatment of therapy-resistant graft-versus-host disease. *Transplantation* 81: 1390-1397, 2006.
 - 8) Le Blanc K, Frassoni F, Ball L et al.: Mesenchymal stem cells for treatment of steroid-resistant, severe, acute graft-versus-host diseases: a phase II study. *Lancet* 371: 1579-1586, 2008.
 - 9) Sato K, Ozaki K, Oh I et al.: Nitric oxide plays a critical role in suppression of T-cell proliferation by mesenchymal stem cells. *Blood* 109: 228-234, 2007.
 - 10) Bacigalupo A: Management of acute graft-versus-host disease. *Br J Haematol* 137: 87-98, 2007.
 - 11) Przepiorka D, Weisdorf D, Martin P et al.: 1994 Consensus Conference on Acute GVHD Grading: *Bone Marrow Transplantation* 15: 825-855, 1995.
 - 12) Pittenger MF, Mackay AM, Beck SC et al.: Multi-lineage potential of adult human mesenchymal stem cells. *Science* 284: 143-147, 1999.
 - 13) Sato K, Ozaki K, Mori M et al.: Mesenchymal stromal cells for graft-versus-host disease : basic aspects and clinical outcomes. *J Clin Exp Hematop* 50: 79-89, 2010.
 - 14) Mori M, Muroi K, Sato K, et al.: Treatment with mesenchymal stem cells against steroid-resistant acute graft-versus-host disease after hematopoietic stem cell transplantation. The 16th annual meeting JSGT2010, abstract p.274, 2010.
 - 15) Remberger M, Aschan J, Barkholt L et al.: Treatment of severe acute graft-versus-host disease with anti-thymocyte globulin. *Clin Transplant* 15: 147-153, 2001.
 - 16) Kebriaei P, Isola L, Bahceci E et al.: Adult human mesenchymal stem cells added to corticosteroid therapy for the treatment of acute graft-versus-host disease. *Biol Blood Marrow Transplant* 15: 804-811, 2009.
 - 17) Bernardo ME, Zaffaroni N, Novara F et al.: Human bone marrow derived mesenchymal stem cells do not undergo transformation after long-term in vitro culture and do not exhibit telomere maintenance. *Cancer Res* 67: 9142-9149, 2007.
 - 18) Colter DC, Sekiya I and Prockop DJ: Identification of a subpopulation of rapidly self-renewing and multipotential adult stem cells in colonies of human marrow stromal cells. *Proc Natl Acad Sci USA* 98: 7841-7845, 2001.
 - 19) Sekiya I, Larson BL, Smith JR et al.: Expansion of human adult stem cells from bone marrow stroma: conditioning that maximize the yields of early progenitors and evaluate their quality. *Stem Cells* 20: 530-531, 2002.
 - 20) Miura M, Miura Y, Padilla-Nash HM et al.: Accumulated chromosomal instability in murine bone marrow mesenchymal stem cells leads to malignant transformation. *Stem Cells* 24: 1065-1103, 2006.
 - 21) von Bonin M, Stölzel F, Goedecke A et al.: Treatment of refractory acute GVHD with third-party MSC expanded in platelet lysate-containing medium. *Bone Marrow Transplant* 43: 245-251, 2009.
 - 22) Sudres M, Norol F, Trenado A et al.: Bone marrow mesenchymal stem cells suppress lymphocyte proliferation in vitro but fail to prevent graft-versus-host disease in mice. *J Immunol* 176: 7761-7767, 2006.

ステロイド抵抗性移植片対宿主病に対する 間葉系幹細胞を用いた新規治療のパイロット試験

佐藤 一也^{*1}, 室井 一男^{*1}, 岡 智子^{*2}, 笹崎 美幸^{*1},
 細沼 里江^{*1}, 尾崎 勝俊^{*1}, 藤原慎一郎^{*1}, 翁 家^{*1},
 松山 智洋^{*1}, 大嶺 謙^{*1}, 鈴木 隆浩^{*1}, 森 政樹^{*1},
 永井 正^{*1}, 小澤 敬也^{*1}

要 約

間葉系幹細胞 (MSC) は、免疫抑制効果を有し造血幹細胞移植後の重症移植片対宿主病 (GVHD) を改善すると報告されている。我々は、ステロイド抵抗性 GVHD に対し、ヒト MSC を投与する臨床研究を実施した。2006年1月から2010年12月にかけて10例 (男性7例, 女性3例), 平均年齢37.9歳 (23歳から65歳まで) のステロイド抵抗性 GVHD を有する患者が本試験に参加した。MSC は、患者の血縁者の骨髓血から分離された。10例中3例で MSC が投与された。他の7例では、大量のメチルプレドニゾロンを含む他の免疫抑制剤の追加によって GVHD が改善した, GVHD が自然に軽快した, または早期死亡のため MSC は投与されな

かった。MSC を投与された3例のうち, 1例で消化管 GVHD の改善を認め, 他の1例では消化管 GVHD の改善なく, 他の1例では消化管 GVHD の増悪なくプレドニゾロンの減量が可能であった。MSC の投与に関係した急性の副作用はみられなかった。今回の臨床研究は少数例での検討であるため, ステロイド抵抗性 GVHD に対する MSC の有効性を評価するのは困難である。ステロイド抵抗性 GVHD に対するヒト MSC の臨床効果を確立するため, 更なる臨床試験が必要である。

(キーワード: 間葉系幹細胞, 移植片対宿主病, 造血幹細胞移植)

* 1 自治医科大学内科学講座血液学部門

* 2 大阪医科大学第一内科